Open Access

Berl Münch Tierärztl Wochenschr
DOI 10.2376/0005-9366-16074

ISSN 0005-9366

Korrespondenzadresse:
schusser@vetmed.uni-leipzig.de

Eingegangen: 15.09.2016
Angenommen: 02.11.2016

Online first: 17.11.2016
http://vetline.de/open-access/158/3216/

Department of Large Animal Medicine, Veterinary Faculty, University of Leipzig, Leipzig, Germany[1]
Kirchheim Equine Hospital, Kirchheim, Germany[2]
Animal Hospital, Domain Karthaus, Germany[3]
Clinic for Horses, Foundation Tierärztliche Hochschule Hannover, Hannover, Germany[4]
Equine Clinic Munich Riem, Munich, Germany[5]
Equine Clinic, Telgte, Germany[6]
Equine Clinic in Sottrum, Sottrum, Germany[7]
Equine Clinic Seester, Seester, Germany[8]
Institute of Pathology, Veterinary Faculty, University of Leipzig, Leipzig, Germany[9]

Multi-centre study on the evaluation of alcohol dehydrogenase activity in the serum of horses with intestinal strangulation

Multizentrische Studie über die Evaluierung der Alkoholdehydogenaseaktivität im Serum von Pferden mit Strangulationsileus

Gàbor Köller[1], Maike Breitenstein[1], Nicole Graneß[1], Stephan Recknagel[1], Rosa Barsnick[2], Ulrich Walliser[2], Wolfgang Scheidemann[3], Astrid Bienert-Zeit[4], Dietz Donandt[5], Guido Stadtbäumer[6], Michael Paar[7], Helmut Hell[8], Heinz-Adolf Schoon[9], Gerald Fritz Schusser[1]

Summary

The diagnosis and especially the prognosis in horses with strangulating obstructions represent a particular challenge for the veterinarian. Reliable parameters are needed to facilitate choosing the right therapy.
In a study of Gomaa et al. (2011) it was found out that alcohol dehydrogenase (ADH) with an activity of > 80 U/L in colic horses with small intestinal strangulation indicated for non-surviving with a sensitivity of 66.7% and a specificity of 94.4%. This current study documents the ADH activity in the serum of 70 horses with small intestinal strangulation and 11 horses with strangulation of the large intestine. Samples of all strangulated intestinal segments were evaluated histologically and clinical data of the horses were collected. The aim of this study was to investigate the relationship between serum ADH activity and the histologically detectable epithelial damage of the ischemic intestine, and the duration of colic, length of the strangulated intestinal part and clinical outcome. Horses with a colic duration of ≥ 4 hours and a ≥ 300 cm strangulated small intestine had significantly increased ADH activity of 41 U/L (median) compared to normal horses (16.3 U/L) and the ROC selected a cut-off value of 25 U/L with a sensitivity of 100% and a specificity of 77%. These horses had complete loss of the villus epithelium with necrosis of the epithelial crypt cells, which indicate a resection of the gut segment involved. Serum ADH activity was below 80 U/L in all horses that survived an intestinal resection.

Keywords: colic, gut ischemia, epithelial alteration, alcohol dehydrogenase, prognostic marker

Zusammenfassung

Die Diagnose und speziell die Prognose für ein Pferd mit einem Strangulationsileus ist eine besondere Herausforderung für den Tierarzt, wobei Marker erforderlich sind, um die richtige Therapie zu wählen. Dabei erwies sich in der Studie von Gomaa et al. (2011), dass die Alkoholdehydrogenase (ADH) mit einer Aktivität > 80 U/L bei Kolikpferden mit einem Strangulationsileus auf ein Nicht-Überleben mit einer Sensitivität von 66,7 % und eine Spezifität von 94,4 % hinweist. In dieser Studie wurden die ADH-Aktivitäten von 70 Pferden mit Dünndarm- und von 11 Pferden mit Kolonstrangulation gemessen. Gewebeproben von den strangu-

U.S. Copyright Clearance Center Code Statement:
0005-9366/2016/16074 $ 15.00/0

lierten Darmsegmenten wurden entnommen und die Epithelalteration histologisch beurteilt und die Kolikdauer sowie die Länge des strangulierten Darmteiles dokumentiert. Das Ziel dieser Arbeit war es, den Zusammenhang zwischen ADH-Aktivität und Epithelalteration des ischämischen Darmteiles zu eruieren. Pferde mit einer Kolikdauer ≥ 4 Stunden und einer Länge des strangulierten Darmteiles ≥ 300 cm hatten signifikant höhere ADH-Aktivitäten (41 U/L, median) in Vergleich zu Normalpferden (16,3 U/L, median). Diese Pferde hatten einen kompletten Verlust der Epithelzellen der Villi mit nekrotischen Kryptepithelzellen, der auf eine Resektion des involvierten Darmteiles hinwies, wobei ein cut-off-Wert von 25 U/L bei einer Sensitivität von 100 % und einer Spezifität von 77 % ermittelt werden konnte. Die Serum-ADH-Aktivitäten lagen unter 80 U/L bei den Pferden, die mit Dünndarmresektion überlebten.

Schlüsselwörter: Kolik, Darmischämie, Epithelalteration, Alkoholdehydrogenase, Prognosemarker

Introduction

A common cause of life-threatening colic in horses is strangulating intestinal obstruction. The short-term survival rate in colic horses with strangulation of the small intestine following small intestine resection ranges between 48–88% (Morton and Blikslager, 2002). A total of 79% of horses with small intestinal strangulation do not survive (Christophersen et al., 2014). Numerous parameters are available to assist the veterinarian evaluating the individual cases of acute colic regarding diagnosis and prognosis. Clinical signs, laboratory values, the response of the horse to analgesics and abdominal ultrasonography provide important information (van der Linden et al., 2003; Dukti and White, 2009). Despite these multiple methods of investigation, however, the definitive diagnosis and a prognostically accurate assessment can often only be made by a laparotomy. There still is a need for reliable parameters which accurately display the degree or magnitude of gut damage helping to make a more refined diagnosis and better prognosis before the surgical decision. In this context, Gomaa et al. (2011) examined the activity of alcohol dehydrogenase (ADH) in the serum of horses with intestinal obstruction. The results suggested that ADH might be a useful parameter for diagnosis and prognosis in horses with intestinal strangulation.

Alcohol dehydrogenase plays an important role in cellular detoxification mechanisms in the bodies of mammals (Ashmarin et al., 2000). It occurs in all tissues, with higher concentrations in the centrilobular part of liver acinus (Kato et al., 1990). In rats, ADH was demonstrated to be a useful marker of intestinal ischemia after occlusion of the mesenteric artery for 1 h (Gumaste et al., 2005). An increased transcription rate of ADH in the liver caused by endotoxemia is assumed to be the reason for the activation of ADH in relation to intestinal ischemia (Potter et al., 2003). Intestinal ischemia causes changes in cell morphology and leads finally to the death of epithelial cells caused by oxygen and energy deficiency. The cells at the tips of the villi are affected first, particularly because of their location at the end of an arteriole, they are already located in an area of low oxygen saturation (Takeyoshi et al., 1996; Kong et al., 1998; Vollmar and Menger, 2011). Therefore, epithelial damage begins at the tip of the villi and proceeds into the crypts (White et al., 1980). As a consequence of ischemia, an increase in epithelial and capillary permeability occurs (Snyder et al., 1992; Darien et al., 1995; Swank and Deitch, 1996). With increasing epithelial damage, more bacterial lipopolysaccharides, chemotactic peptides and bacteria enter the blood stream through the mucosa and cause endotoxemia (Snyder, 1989; Tomlinson et al., 2004). Kupfer cells are activated in the liver acinus and produce cytokines and superoxides, which again lead to more liver cell damage (Morris, 1991; Su, 2002; McDonald et al., 2013). Endotoxins cause an increased transcription rate of ADH in the liver cells and liver cell damage (Su, 2002; Potter et al., 2003). Both results increase the levels of ADH in serum. Based on this, the hypothesis of this study was that in the case of intestinal strangulation, serum ADH levels increase in correlation to the degree of mucosal damage, to the length of the strangulated intestinal segment and to the duration of colic.

Material and Methods

This multi center study was conducted between 2012 and 2014. A total of 70 horses with a median age of 16.5 years (first = Q1 10.75 and third quartile = Q3 20, min 1, max 24) with small intestine strangulation obstruction were examined. The following clinical parameters were collected from each horse: the cause and duration of the colic and length of the ischemic small intestine (ism). Group A included horses with colic duration (cd) of ≥ 4 h and ≥ 300 cm gut affected. Group B contained all other horses with small intestine strangulation. Additionally, eleven adult horses with colon strangulation (median age 15 years; Q1 13, Q3 21, min 7 and max 26) were included. All horses with colon strangulation were euthanized either without a surgery attempt or intraoperatively. Samples of the intestinal wall were collected from the part of the intestine affected for histological examination. These results have been published elsewhere (Breitenstein et al., 2015).

Blood samples of 81 horses with colic were taken immediately before euthanasia or surgery. Ten clinically healthy adult Warmblood horses were used as a reference group. The median age was 10.5 years (Q1 7.75, Q3 11.75, min 6, max 16).

The samples were placed in blood collection tubes without anticoagulant and were centrifuged after 30 min for 10 min at 1500 g. The supernatant (serum) was transferred to an Eppendorf tube and stored at –20°C until

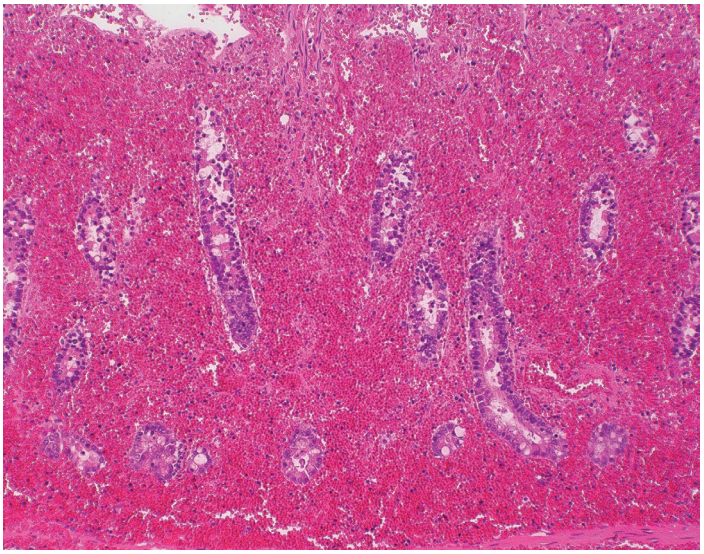

FIGURE 1: *Small intestinal mucosa induced by strangulation of a lipoma, length of ischemic part of the bowel 100 cm, colic duration 5 hours; graduation of epithelial alteration: villus luminal and basal 5/5, crypt luminal 5/5, crypt central 4/5 and basal 3/5; hemorrhage 4/4; inflammation 0/3 (graduated by Breitenstein et al. 2015), ADH 48/L, resection of the ischemic segment, horse survived.*

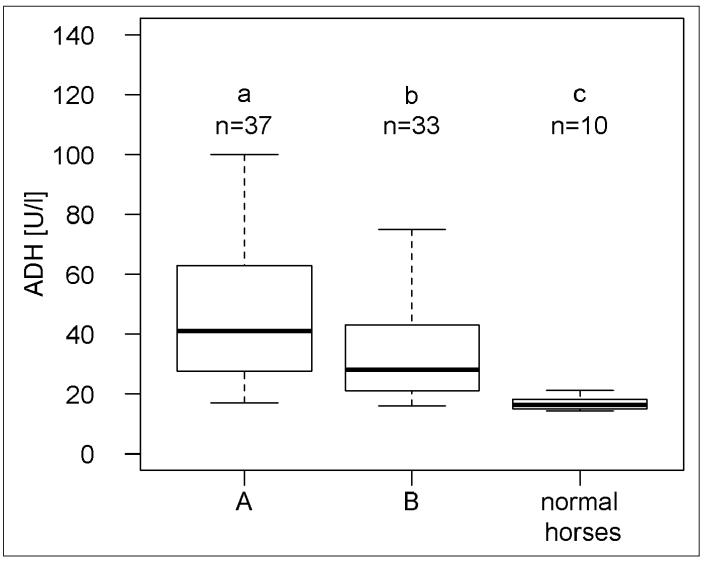

FIGURE 2: *Boxplot of ADH activity in U/L of horses with small intestinal strangulation in group A which had a colic duration (cd) of ≥ 4 h and ≥ 300 cm ischemic gut. Group B included horses with colic with < 4 h cd and < 300 cm, > 4 h cd and < 300 cm, < 4 h cd and > 300 cm of ischemic gut. All groups are significantly different to each other; P value ≤ 0.05.*

analysis. The ADH activity was measured according to the method of Gomaa et al. (2011). The measurement of ADH in serum was performed with a standard test (Cobas C311, Roche Diagnostics, Mannheim, Germany). The alteration of the epithelial cells in the tissue samples collected was graded for comparison between the intestinal ischemia in the strangulated gut segment and the increase of ADH activity in the serum of these horses with colic. An evaluation scale established by van Hoogmoed et al. (2004) was used to characterize the mucosal epithelial alterations in the ischemic small and large intestine involved as moderate, severe or profound. Representative samples, with a size of approximately 2 × 2 cm, from anti-mesenteric regions of the strangulated gut, including all intestinal wall layers, were collected and fixed in 4% formalin solution for at least 48 h. The samples were cut and embedded in Paraplast (Fa. Vogel, Giessen, Germany). Two microtome sections (Fa. Leica, Wetzlar, Germany), each with a thickness of 2–4 µm, were cut from each tissue sample, placed on slides and stained with hematoxylin-eosin. The samples were evaluated under a light microscope (BH2, Olympus, Hamburg, Germany) at 400 x magnification, and 5 representative locations of each slide were examined and graded. Based on the study of Breitenstein et al. (2015), the crypt epithelial necrosis was evaluated in more detail by distinguishing cellular degeneration above or below 50% of the crypt epithelial cells (Fig. 1). Cellular alteration was defined by the degree of cellular edema, a flaky cytoplasmatic structure, deformation of the nucleus up to complete karyolysis and the detachment of the epithelial basement membrane.

Statistical analysis

The Shapiro-Wilk test was used to assess the data normality. None of the data was normally distributed. Therefore, median and interquartile ranges were calculated and the results are presented as median with the first (Q1) and third quartile (Q3). Logistic regression analysis was used to check the relationship between ADH activity and the probability that a horse with small intestine strangulation had profound epithelial alteration of the involved small intestinal segment. Receiver operating characteristic curve was constructed to determine the cut-off value that discriminates horses with strangulated small intestine with profound epithelial alteration of the crypt cells and where the involved gut segment should be removed, from horses with normal epithelial crypt cells in the small intestine. Nonparametric comparisons between the groups were computed with the Wilcoxon signed-rank test, using a statistical software program R (R Core Team, 2016). Significance was set at $p \leq 0.05$.

Results

Group A included 37 horses with colic of a colic duration of ≥ 4 h and ≥ 300 cm ischemic segment. Group B incorporated 33 horses with colic (cd < 4 h and < 300 cm ism, > 4 h and < 300 cm ism, < 4 h and > 300 cm ism). The ADH activities of these two groups are listed in Table 1. Group A had a significantly higher ADH activity than group B and the clinically healthy horses (Fig. 2).
The numbers of horses having colic with moderate, severe or profound epithelial alteration of the crypts and/or villi and their ADH activities are described in Table 2. The ADH activities of horses with small intestinal strangulation and severe or profound degenerated crypt cells were significantly increased in comparison to normal horses.

Clinical outcome

Of the 70 horses with small intestinal strangulation, 52 horses were euthanized (13 horses due to lack of surgery permission, 31 horses due to poor intraoperative prognosis, 8 horses soon after involved gut resection).

The median ADH activity of these horses euthanized was 34 U/L (Q1 23, Q3 50.3, min 16, max 138). None of the horses with an ADH activity of > 80 U/L (n = 7) survived. 45 horses with an ADH activity < 80 U/L were euthanized (12 were euthanized due to lack of surgery permission, 28 were euthanized intraoperatively and 5 died soon after resection was performed). However, 18/70 horses survived but were discharged after successful resection. The median ADH activity in the discharged horses was 42.5 U/L (Q1 23.5, Q3 48.8, min 20, max 78.4), this measured value being less than 80 U/L.

An association between profound epithelial damage of the crypt cells of the ischemic small intestinal segment and increasing ADH activity was noted, which ascended significantly ($p \leq 0.05$) in comparison to the normal values (Tab. 2.). Receiver operating characteristics (ROC) curve for sensitivity and 1-specificity (= false positive rate) of these cut-off values indicate their high performance in differentiation between normal horses and horses with strangulated small intestine which have profound altered epithelium in the crypts (Fig. 3). This was confirmed by the AUC 0.94. It appears that a serum ADH activity of 25 U/L is the optimal cut-off that yields the highest sensitivity (100%) and specificity (77%) for the test (Tab. 3).

All horses with colon strangulation were euthanized either without a surgery attempt or intraoperatively. The median ADH activity was 36.3 U/L (Q1 27, Q3 61.5, min 12, max 155). The median of colic duration was 6 h (Q1 5.5, Q3 10, min 3, max 35).

TABLE 1: *ADH activities in U/L of horses with small intestine strangulation in group A which had a colic duration (cd) of ≥ 4 h and ≥ 300 cm ischemic gut. Group B included horses with colic with < 4 h cd and < 300 cm, > 4 h cd and < 300 cm, < 4 h cd and > 300 cm of ischemic gut. The group A or B are significantly different to normal horses; groups with different letters are significantly different; P value ≤ 0.05*

Group of horses with colic	n	ADH activity U/L					Significant difference
		min	Q1	median	Q3	max	
A	37	17.0	27.6	41.0	63.0	138.0	a
B	33	16.0	21.0	28.1	43.0	120.0	b
Normal horses	10	14.2	15.2	16.3	17.8	21.20	c

Discussion

In the current study, it was found that increased ADH activity in horses with small intestinal strangulation was associated with the length of the strangulated part of the intestine and the colic duration (Tab. 1 and Fig. 2). The measurement of lactate is commonly used for the diagnostic and prognostic assessment in horses with colic (Yamout et al., 2011; Peloso and Cohen, 2012; Tennent-Brown, 2012). However, the lactate value measured is not always reliable, because lactate is produced not only in the strangulated portion of the intestine, but also in any hypoxic tissue. Colic horses with a colic duration of less than four hours and a proximal strangulation of the small intestine had mostly a hypochloremic metabolic alkalosis due to gastric reflux and therefore these colic horses had no lactatemia measured < 3 mmol/L (unpublished data; Spurlock and Ward, 1990; Gomaa et al., 2011). In our study 7 horses with small intestinal strangulation and a colic duration of less than four hours had ADH activities between 20 and 60 U/L of ADH. Furthermore, a correlation between the length of the strangulated intestine and lactate values in both, blood and peritoneal fluid, has not been detected, however only the peritoneal fluid lactate concentration higher than 8.45 mmol/L is a better predictor of ischemic strangulated gut (Ebert, 1994; Latson and Nieto, 2005). Establishing a more reliable or more specific marker for intestinal hypoxemia is an important goal in clinical colic research. The present study shows that serum ADH activity is influenced by the length of

TABLE 2: *Grading scheme for the evaluation of epithelial alteration of the small intestine and the amount of the degeneration of crypt epithelial cells established by van Hoogmoed et al. (2004). All horses with colic having severe or profound epithelial crypt cell alteration in the ischemic small intestine had significantly increased ADH activity in comparison to normal horses (p ≤ 0.05)*

Horses	Grading of epithelial alteration described by Breitenstein et al. (2015)	Epithelial alteration of the small intestine involved described by van Hoogmoed et al. (2004)	Amount of degenerated epithelial cells in the crypts	Grading of epithelial alteration	Horses with small intestinal strangulation	Serum ADH activity (U/L) median (Q1, Q3)
Normal horses (n = 10)	0	Small intestinal villi anatomically normal, closely attached mucosal epithelial crypt cells	0%			16.3 (15.2, 17.8)
Colic horses (n = 70)	1	Epithelial separation from the basement membrane at the tip of the villus	Separation of the epithelial cells from the basement membrane or lamina propria of the villi, no degenerated crypt cells	moderate	n = 18	32 (23.25, 43.17)
	2	Separation of epithelial cells from the lamina propria at the tip of the villus				
	3	Lifting of epithelial cells at the tip of the villus				
	4	Sloughing of epithelial cells at least half the distance of the villus				
	5	Complete loss of the villus epithelium with necrosis of the epithelial crypt cells	Less than 50% degenerated crypt cells	severe	n = 36	34 (20.75, 55.12)
			More than 50% degenerated crypt cells	profound	n = 16	41 (31.25, 51)

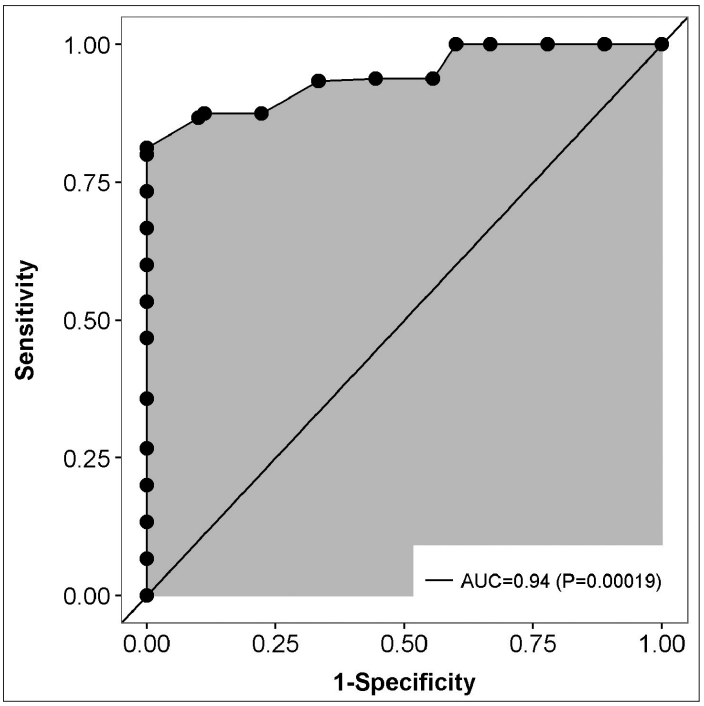

FIGURE 3: *The receiver operating characteristics curve illustrates the association between cut-off values of alcohol dehydrogenase (ADH) activity, differentiating between horses with strangulated small intestine and profound altered epithelium in the crypts of involved small intestine and horses with normal epithelial cells in the crypts, the sensitivity and 1-specificity. The optimal cut-off value is located closest to the upper left corner. At this cut-off value of 25 U/L, the sensitivity is 100% and specificity is 77%.*

the strangulated intestinal segment. Thus, lactate and ADH could complement each other potentially with regard to diagnosis and prognosis in horses with colic (Gomaa et al., 2011).

The median ADH activity increased significantly with the degree of damage of the small intestinal epithelium (Tab. 2). No correlation between the degree of epithelial damage and the duration of the colic could be detected (Breitenstein et al., 2015). Blood flow has to be reduced by at least 50% of the physiological amount to cause an oxygen deficit in the intestinal tissue (Bulkley et al., 1985). The degree of endotoxemia and hence the level of blood ADH activity is affected by the amount of blood, which is still able to pass into the strangulated part of the intestine, or if the blood flow is even completely interrupted (Gomaa et al., 2011).

In the case of damage in the colon mucosa due to colon torsion, more endotoxin crosses into the blood than in small intestinal damage, therefore, higher ADH activation is expected in horses with diseases of the large colon (Gomaa et al., 2011). However, samples from horses with a strangulated colon examined here showed the maximum value of 155 U/L measured in a horse with colon torsion. The highest activity of ADH measured in a horse with small intestinal strangulation was 138 U/L. This horse died after resection was performed.

Gomaa et al. (2011) showed an increased ADH activity in the serum of horses with strangulating obstruction (large or small intestine) in 23 out of 29 cases. The present study supports these findings. An ADH activity of > 20 U/L was determined in 67 out of 81 horses (82.7%) with large or small intestinal strangulation. All 7 horses with an ADH activity > 80 U/L died or were euthanized. Thus, ADH activity can be used to assess the prognosis for survival in horses with small intestinal strangulation obstruction. Strangulation of the small intestine induces epithelial alteration of the mucosa due to ischemia. The loss of the epithelial cells begins at the tip of the villi of the gut segment involved and comes down to the crypts within 4–6 h of colic duration (Breitenstein et al., 2015). Horses with profound epithelial alterations or 5/5 graded epithelial damage of the strangulated small intestine scored by van Hoogmoed et al. (2004) or described by Breitenstein et al. (2015) have significantly higher ADH activity compared to normal horses (Tab. 2). Based on this study, the increased ADH activity higher than 41 U/L indicates a profound epithelial alteration with complete loss of the villus epithelium and with necrosis of the epithelial crypt cells, which indicates the need of a resection of the gut segment involved. But an ADH activity higher than 25 U/L represented by the receiver operation characteristics (Tab. 3, Fig. 3) suggested an alteration of the crypt cells (less or more than 50% degenerated crypt cells) in the involved segment of the small intestine. These 2 found ADH activity limits could be used as a prognostic marker for the decision if a resection is not required or if the ischemic gut segment should be resected. Apart from that only clinical criteria of viability of the ischemic gut segment after correction of the strangulation described by Freeman (2008) are available: serosal color, bowell wall thickness, presence or absence of mesenteric arterial pules and spontaneous motility which were graded from I (e. g. serosal color = pink = no resection) to V (e. g. serosal color = gray, black or green = have to be resected).

The present study showed that ADH can be used as a useful marker in the assessment of horses with acute colic. A longer colic duration and section of the strangulated

TABLE 3: *The cut-off values of serum ADH activity (U/L) differentiate between 16 horses with small intestinal strangulation and profound epithelial crypt cell alterations in the involved gut segment and 10 normal horses with normal epithelial crypt cells in the small intestine. Number of horses with small intestinal strangulation and profound crypt alterations and ADH activity greater than the corresponding cut-off value (True positive); number of horses with normal crypt cells and ADH activity lower than the corresponding cut-off value (True negative)*

ADH cut-off value	20	25	30	40	50	60
Number of horses with profound crypt alterations/number horses with normal crypt cells	14/9	13/10	12/10	9/10	4/10	4/10
Sensitivity %	93	100	100	100	100	100
CI %	68–100	66–100	64–100	55–100	28–100	28–100
Specificity %	82	77	71	59	45	45
CI %	48–98	46–95	42–92	33–82	28–68	28–68
Positive predictive value %	88	81	75	56	25	25
CI %	62–98	54–96	48–93	30–80	7–52	7–52
Negative predictive value %	90	100	100	100	100	100
CI %	55–100	59–100	59–100	59–100	59–100	59–100

intestine correlated with a higher degree of epithelial alterations and lead to a higher ADH activity, which could be an indicator for gut resection. This could be important information for the surgeon's decision. If the ADH activity is > 80 U/L, it can be expected that the horse will not survive, a verification already made by Gomaa et al. (2011).

Conflict of interest

The authors declare that there is no protected, financial, occupational or other personal interest in a product, service and/or a company which could influence the contents or opinions presented in the manuscript.

References

Ashmarin IP, Danilova RA, Obukhova MF, Moskvitina TA, Prosorovsky VN (2000): Main ethanol metabolizing alcohol dehydrogenases (ADH I and ADH IV): Biochemical functions and the physiological manifestation. FEBS Lett 486: 49–51.

Bulkley GB, Kvietys PR, Parks DA, Perry MA, Granger DN (1985): Relationship of blood flow and oxygen consumption to ischemic injury in the canine small intestine. Gastroenterology 89: 852–857.

Breitenstein M, Theuß T, Schoon HA, Barsnick R, Walliser U, Scheidemann W, Bienert A, Donandt D, Stadtbäumer G, Werhahn H, Hell H, Snyder A, Schusser GF (2015): Klinische Feldstudie zur Evaluierung und Graduierung histomorphologischer Veränderungen ischämischer Dünn- oder Dickdarmregionen nach Strangulation. Pferdeheilkunde 31: 559–570.

Christophersen MT, Dupont N, Berg-Sørensen KS, Konnerup C, Pihl TH, Andersen PH (2014): Short-term survival and mortality rates in a retrospective study of colic in 1588 Danish horses. Acta Vet Scand 56(Ci): 20.

Darien BJ, Stone WC, Dubielzig RR, Clayton MK (1995): Morphologic changes of the ascending colon during experimental ischemia and reperfusion in ponies. Vet Pathol 32: 280–288.

Dukti S, White N (2009): Prognosticating equine colic. Vet Clin North Am Equine Pract 25: 217–231.

Ebert R (1994): Prognostic parameters in equine colic. Tierärztl Praxis 22: 256–263.

Freeman DE (2008): Intestinal viability, In: White N, Moore J, Mair T (eds.), The equine acute abdomen. Teton Media, Jackson, 502–512.

Gomaa NA, Köller G, Schusser GF (2011): Clinical evaluation of serum alcohol dehydrogenase activity in horses with acute intestinal obstruction. J Vet Emerg Crit Care 21: 242–252

Gumaste UR, Joshi MM, Mourya DT, Barde PV, Shrivastav GK, Ghole VS (2005): Alcohol dehydrogenase: a potential new marker for diagnosis of intestinal ischemia using rat as a model. World J Gastroenterol 11: 912–916.

Kato S, Ishii H, Aiso S, Yamashita S, Ito D, Tsuchiya M (1990): Histochemical and immunohistochemical evidence for hepatic zone 3 distribution of alcohol dehydrogenase in rats. Hepatology 12: 66–69.

Kong SE, Blennerhassett LR, Heel KA, McCauley RD, Hall JC (1998): Ischaemia-reperfusion injury to the intestine. Aust N Z J Surg 68: 554–561.

Latson KM, Nieto JE (2005): Evaluation of peritoneal fluid lactate as a marker of intestinal ischemia in equine colic. Equine Vet J 37: 342–346.

McDonald B, Jenne CN, Zhuo L, Kimata K, Kubes P (2013): Kupffer cells and activation of endothelial TLR4 coordinate neutrophil adhesion within liver sinusoids during endotoxemia. Am J Physiol Gastrointest Liver Physiol. 305: 797–806.

Morris DD (1991): Endotoxemia in horses. A review of cellular and humoral mediator involved in its pathogenesis. J Vet Intern Med 20: 167–181.

Morton AJ, Blikslager (2002): Surgical and postoperative factors influencing short-term survival of horses following small intestinal resection: 92 cases (1994–2001). Equine vet J 34: 450–454.

Peloso JG, Cohen ND (2012): Use of serial measurements of peritoneal fluid lactate concentration to identify strangulating intestinal lesions in referred horses with signs of colic. J Am Vet Med Assoc. 240: 1208–1217.

Potter JJ, Rennie-Tankersley L, Mezey E (2003): Endotoxin enhances liver alcohol dehydrogenase by action through upstream stimulatory factor but not by nuclear factor-kappaB. J Biol Chem 278: 4353–4357.

R Core Team (2016): R: A language and environment for statistical computing. R Foundation for Statistical Computing, Vienna, Austria.

Snyder JR (1989): The pathophysiology of intestinal damage: effects of luminal distention and ischemia. Vet Clin North Am Equine Pract 5: 247–270.

Snyder JR, Pascoe JR, Olander HJ, Harmon FA, Hinds DM, Vatistasa NJ, Tyler WS (1992): Ultrastructural mucosal injury after experimental ischemia of the ascending colon in horses. Am J Vet Res 53: 1917–1924.

Spurlock SL, Ward MV (1990): Fluid therapy for abdominal disease. In: White NA (ed.), The equine acute abdomen. London: Lea & Febiger, Philadelphia, 160–172.

Su GL (2002): Lipopolysaccharides in liver injury: molecular mechanisms of Kupffer cell activation. Am J Physiol Gastrointest Liver Physiol 283: G256–265.

Swank GM, Deitch EA (1996): Role of the gut in multiple organ failure: bacterial translocation and permeability changes. World J Surg 20: 411–417.

Takeyoshi I, Zhang S, Nakamura K, Ikoma A, Zhu Y, Starzl TE, Todo S (1996): Effect of ischemia on the canine large bowel: a comparison with the small intestine. J Surg Res 62: 41–48.

Tennent-Brown BS (2012): Interpreting lactate measurement in critically ill horses: diagnosis, treatment, and prognosis. Compend Contin Educ Vet 34(1):E2.

Tomlinson JE, Wilder BO, Young KM, Blikslager AT (2004): Effects of flunixinmeglumine or etodolac treatment on mucosal recovery of equine jejunum after ischemia. Am J Vet Res 65: 761–769.

Van der Linden M, Laffont CM, Sloet van Oldruitenborgh-Oosterbaan MM (2003): Prognosis in equine medical and surgical colic. J Vet Intern Med 17: 343–348.

Van Hoogmoed LM, Nieto JE, Spier SJ, Snyder JR (2004): In vivo investigation of the efficacy of a customized solution to attenuate injury following low-flow ischemia and reperfusion injury in the jejunum of horses. Am J Vet Res 65: 485–490.

Vollmar B, Menger MD (2011): Intestinal ischemia/reperfusion: microcirculatory pathology and functional consequences. Langenbecks Arch Surg 396: 13–29.

White NA, Moore JN, Trim CM (1980): Mucosal alterations in experimentally induced small intestinal strangulation obstruction in ponies. Am J Vet Res 41: 193–198.

Yamout SZ, Nieto JE, Beldomenico PM, Dechant JE, leJeune S, Snyder JR (2011): Peritoneal and plasma D-lactate concentrations in horses with colic. Vet Surg 40: 817–824.

Address for correspondence:
Prof. Dr. Gerald Fritz Schusser
Medizinische Tierklinik
Veterinärmedizinische Fakultät der Universität Leipzig
An den Tierkliniken 11
04103 Leipzig
Germany
schusser@vetmed.uni-leipzig.de